

## CLINICAL PRACTICE

## Idiopathic Scoliosis in Adolescents

M. Timothy Hresko, M.D.

*This Journal feature begins with a case vignette highlighting a common clinical problem. Evidence supporting various strategies is then presented, followed by a review of formal guidelines, when they exist. The article ends with the author's clinical recommendations.*

**A 12-year-old girl presents with her parents after a positive school screening for scoliosis. Physical examination reveals shoulder and torso asymmetry with trunk imbalance (i.e., shift from the midline). Neurologic and skin examinations are normal. How should the patient be evaluated and treated?**

## THE CLINICAL PROBLEM

From the Department of Orthopedic Surgery, Boston Children's Hospital, and Harvard Medical School—both in Boston.

N Engl J Med 2013;368:834-41.

DOI: 10.1056/NEJMcpl209063

Copyright © 2013 Massachusetts Medical Society.

Scoliosis is the most common deformity of the spine. Although the term “scoliosis” may be used by some clinicians to describe any curvature of the spine noted on clinical examination or incidental finding on radiography, the term should be reserved for a precise condition. Scoliosis is defined as a lateral curvature of the spine that is 10 degrees or greater on a coronal radiographic image while the patient is in a standing position (although the image is a representation of a three-dimensional deformity).

Scoliosis is typically categorized according to cause. Congenital scoliosis is an anatomical anomaly due to failure of formation or segmentation of the vertebral column which, with growth, may lead to progressive spinal deformity. Neuromuscular scoliosis is deformity caused by dysfunction of the central nervous system (e.g., spastic quadriplegia), dysfunction of the peripheral neuromuscular unit (e.g., muscular dystrophy and spinal muscular atrophy), or combined sensory and motor dysfunction (e.g., syringomyelia). Scoliosis is common in patients with neurofibromatosis and in patients with certain connective-tissue diseases such as Marfan's syndrome or the Ehlers–Danlos syndrome. In most patients with scoliosis, however, the cause is unrecognized (i.e., idiopathic scoliosis). Idiopathic scoliosis is subclassified as infantile (in children from birth up to 3 years of age), juvenile (in children 3 to 10 years of age), adolescent (in children older than 10 years of age), or adult. In adults, the development of scoliosis may be due to degenerative disk disease. First-degree relatives of a person with scoliosis are at increased risk (10% prevalence)<sup>1,2</sup>; this suggests a genetic basis for this condition, but specific genetic determinants remain unclear.<sup>3,4</sup>

Chest and trunk asymmetry, the basis for physical-examination screening for scoliosis, is common in otherwise healthy children and adolescents. Only 1.6% of high-school students have a completely symmetric posture.<sup>5</sup> Of more than 2000 children assessed in a school screening program, 4.1% had a positive result on the basis of visual assessment while the student was standing and while bending forward (the Adams forward-bend test) and measurement of rib prominence, 1.8% had idiopathic scoliosis of greater than 10 degrees, and 0.4% required active treatment.<sup>6</sup>

In the growing child, the primary complication of scoliosis is disfigurement of the torso with shoulder or waist asymmetry, trunk imbalance, or rib rotation. In



An audio version  
of this article is  
available at  
[NEJM.org](http://NEJM.org)

## KEY CLINICAL POINTS

**IDIOPATHIC SCOLIOSIS IN ADOLESCENTS**

- The diagnosis of scoliosis is suspected on the basis of physical examination and is confirmed by radiography, performed while the patient is in a standing position, that reveals spinal curvature of 10 degrees or greater.
- Idiopathic scoliosis is present in 2% of adolescents. Adolescents with scoliosis should have a thorough physical examination to rule out hereditary connective-tissue disorders (e.g., Marfan's syndrome), neurofibromatosis, or neurologic conditions.
- Most adolescents with nonprogressive idiopathic scoliosis can be seen by a primary care physician and do not require active treatment.
- Bracing is commonly recommended in patients with an immature skeleton with curve progression of 25 to 45 degrees, but data to support this approach are observational and inconsistent; a randomized trial comparing bracing with observation for idiopathic scoliosis is currently in progress.
- Surgical treatment is recommended in patients with an immature skeleton who have progressive scoliosis greater than 45 degrees.

a 50-year natural-history study involving patients with untreated idiopathic scoliosis, disfigurement remained the major concern of patients into adulthood.<sup>7</sup> Mild pain is common among children with clinically significant curvature, but severe pain that disrupts function or sleep is atypical and requires evaluation to rule out underlying conditions such as a tumor of the spinal column, an infection, a Chiari I malformation with a syrinx, or a tethered spinal cord.

Idiopathic scoliosis is not progressive in most patients. The likelihood of progression is higher in girls and in children with a large curvature and remaining growth. Natural-history studies have shown that scoliosis deformity that is less than 30 degrees at the end of growth rarely worsens in adulthood, whereas scoliosis of greater than 50 degrees predictably worsens throughout adulthood at a rate of 0.75 to 1.00 degree per year.<sup>8</sup> Therefore, the patient with an immature skeleton with scoliosis of greater than 25 to 30 degrees is at risk for progression.

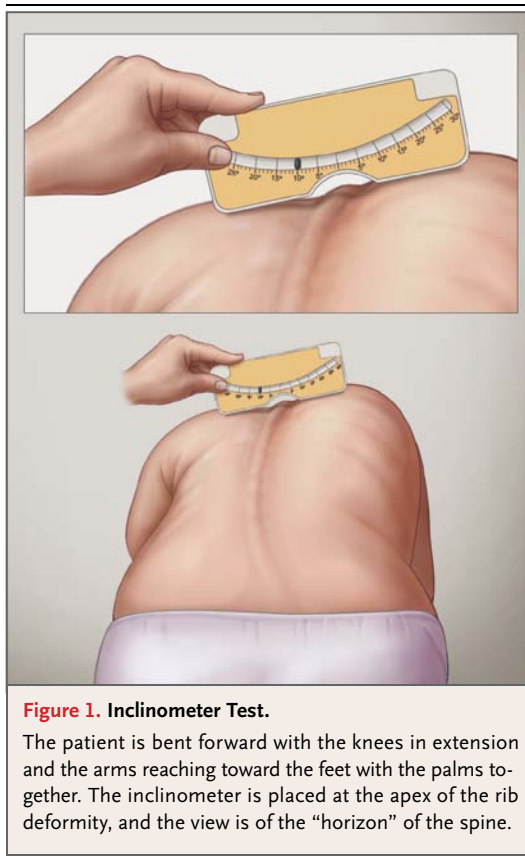
Since lung volume approximately doubles from the age of 10 years to skeletal maturity, growth of the thoracic spine in the preadolescent is necessary to achieve adult chest volume.<sup>9</sup> Adolescent patients with thoracic scoliosis of greater than 50 degrees are at increased risk for shortness of breath later in life (odds ratio, approximately 15 at 30-year follow-up and 4 at 50-year follow-up, as compared with age-matched norms).<sup>7</sup> Lung volumes are diminished as compared with norms

when thoracic idiopathic scoliosis reaches 70 degrees, and symptomatic restrictive pulmonary disease is common in patients with a curve magnitude that exceeds 100 degrees.<sup>10</sup>

## STRATEGIES AND EVIDENCE

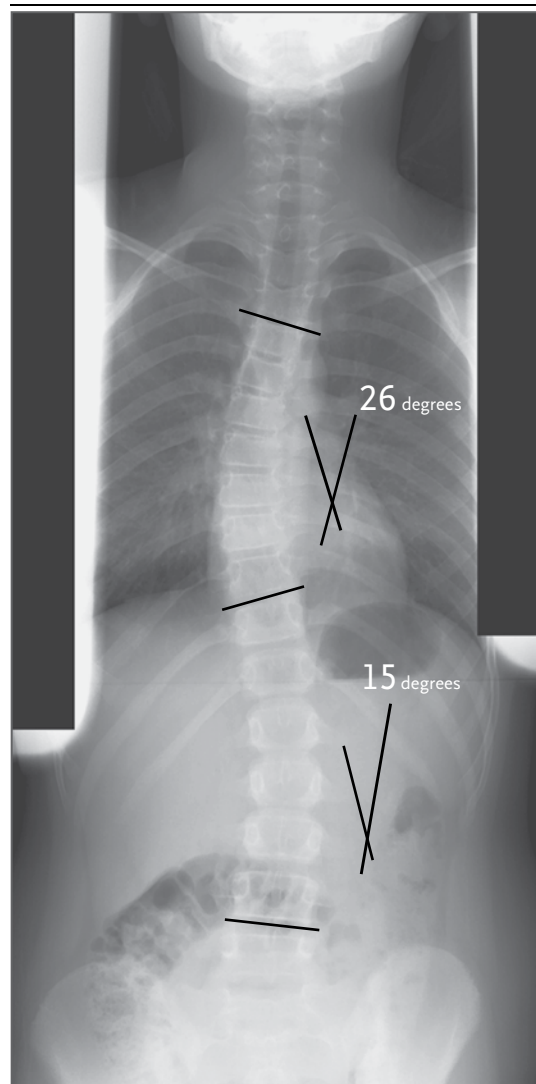
**EVALUATION**

The physical examination is fundamental in the diagnosis of scoliosis and elimination of underlying conditions that may cause spinal deformity. Classic findings of scoliosis on examination are shoulder and scapular asymmetry, rib prominence on forward flexion on the Adams test (Fig. 1), and asymmetry of the waist and trunk. Axial rotation of the trunk on the Adams test can be quantified with an inclinometer; rotation of less than 7 degrees is associated with a 95% probability of a curve that is less than 30 degrees on radiography.<sup>5</sup> Skin examination is warranted to rule out manifestations of neurofibromatosis (e.g., café au lait spots, subcutaneous fibromas, and axillary freckling) and an ectodermal anomaly such as midline spinal dimpling, suggestive of incomplete closure of the neural tube. The extremities should be assessed for arachnodactyly, or joint laxity, which is suggestive of heritable connective-tissue disorders, as well as for inequality in leg length, which may cause a false positive result on the Adams test. If a connective-tissue disorder is suspected, referral for genetic and cardiac evaluation is appropriate. Sensory,



**Figure 1. Inclinometer Test.**

The patient is bent forward with the knees in extension and the arms reaching toward the feet with the palms together. The inclinometer is placed at the apex of the rib deformity, and the view is of the “horizon” of the spine.



**Figure 2. Posteroanterior Radiograph of the Spine in a Patient with an Immature Skeleton.**

The radiograph, which was obtained while the patient was in a standing position, shows a right thoracic scoliosis of 26 degrees from the 4th to the 10th thoracic vertebrae, which is typical of an idiopathic scoliosis. A secondary curve of 15 degrees to the left is shown in the lumbar spine. The Cobb angle of measurement of scoliosis is defined as the angle between a line parallel to the superior vertebrae and a line at the inferior vertebrae of the curve.

reflex, or muscle testing may indicate nerve dysfunction associated with syringomyelia.

Spinal radiography remains the standard of imaging for the evaluation of scoliosis. More than 90% of patients with idiopathic scoliosis will have a convex curvature that is right thoracic or left lumbar scoliosis. An atypical direction or location of the curve should alert the examiner to possible underlying conditions. A posteroanterior radiograph of the spine from C7 to the iliac crest is recommended, obtained with digital-imaging enhancement with the patient in a standing position (Fig. 2); this view reduces radiation exposure to the thyroid and breast tissue. After initial imaging that includes the lateral rib border to assess for rib deformity, a breast shield can be used for subsequent imaging. Lateral images of the spine should be obtained in patients with low back pain or lumbar scoliosis to assess for spondylolisthesis as a cause of the scoliosis. Radiographs obtained while the patient is bending are not needed in routine evaluation but are indicated to evaluate the flexibility of the spine in patients who are candidates for surgery.

Assessment of skeletal maturity is critical in predicting the risk of progression of scoliosis. The growth velocity, as assessed by means of serial height measurements, correlates with the likelihood of progression of scoliosis. In girls, peak growth velocity occurs in the year before

menarche. If serial height data are not available, skeletal maturity is assessed by means of radiography to estimate bone age. A rating of skeletal maturity has been developed that takes into account the appearance of the phalangeal physis and the magnitude of the curvature. This rating may predict the risk of progression to scoliosis that requires surgical treatment, but it is based on limited data.<sup>11</sup> Curvature progression is rare if the magnitude is less than 30 degrees and the patient has reached skeletal maturity (a bone age of 15 years in girls and 17 years in boys, or fusion of the physis on the phalanges and metacarpals).

Magnetic resonance imaging (MRI) is useful in the evaluation of an abnormality of the neural axis, but it is not routinely required.<sup>12</sup> Indications for MRI in patients with idiopathic scoliosis are onset before 10 years of age, kyphotic apex of the scoliosis, clinically significant pain, a neurologic abnormality, neurofibromatosis, or midline cutaneous anomalies (which are known to occur with neural-tube defects). A left thoracic scoliosis is atypical, but this finding alone is not an indication for MRI.<sup>13,14</sup> The onset of scoliosis before 10 years of age is associated with an occult intraspinal abnormality in approximately 20% of patients<sup>13</sup>; MRI of the spine from the craniocervical junction to the sacrum is recommended in this age group if the scoliosis exceeds 20 degrees.

## TREATMENT

### *Nonoperative Therapy*

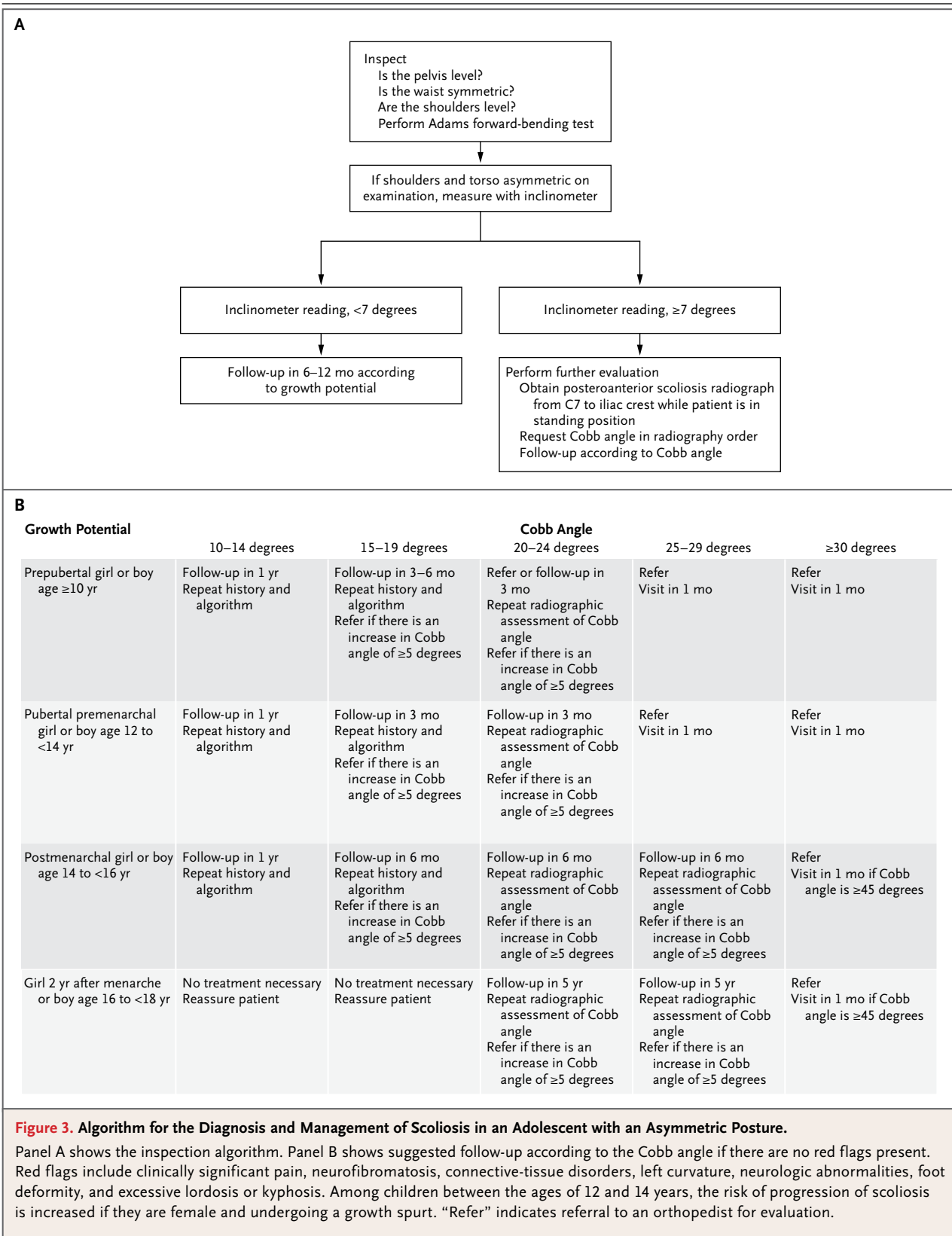
Most patients with nonprogressive idiopathic scoliosis do not require treatment; often, primary care physicians perform periodic assessments during periods of rapid growth. Figure 3 shows an algorithm developed from observational data for the management of scoliosis. The algorithm is based on the clinical examination, age of the patient, and magnitude of the curve.

Many nonoperative treatment options, such as physical therapy, surface electrical stimulation, and chiropractic treatment, have been proposed, but supporting data are lacking from controlled studies. Intervention with the use of a corrective cast program is recommended for progressive deformity in children younger than 3 years of age. Casting is not used in older children for long periods but may be useful in the juvenile patient (3 to 10 years of age) to delay surgical treatment or reduce the curve magnitude before initiation of a bracing program.

Treatment with the use of a rigid thoracolumbar orthotic brace is currently preferred for children 3 years of age through adolescence who are at risk for progressive scoliosis (i.e., patients with a curve magnitude of 25 to 45 degrees and considerable growth remaining). A brace is used to arrest the progression of scoliosis below the level requiring surgical treatment. In a prospective observational study involving girls 10 to 15 years of age with scoliosis of 25 to 35 degrees, the rate of success (defined as progression of <6 degrees) at 4 years was 74% among those who underwent bracing, as compared with 34% in an observation group and 33% in an electrical-stimulation group,<sup>15</sup> but conclusions are limited by the nonrandomized design and loss to follow-up. Results from bracing appear to be most positive when the average daytime brace wear is at least 12 hours; a typical brace prescription is for 18 to 20 hours per day, since full adherence is rarely achieved.<sup>16</sup> The success of brace treatment in preventing progression varied from 22% in an observational retrospective analysis<sup>17</sup> that included all patients who received a brace regardless of adherence to the recommended regimen to 80% in a prospective study<sup>18</sup> when wear exceeded 12 hours during the daytime. Studies of the effectiveness of bracing have been limited by variability in indications for brace therapy (with respect to the risk of progression) and in brace treatment regimens. A multicenter, randomized trial comparing bracing with watchful waiting, the Bracing in Adolescent Idiopathic Scoliosis Trial (BRAIST), is in progress, with enrollment completed (ClinicalTrials.gov number, NCT00448448).<sup>19</sup>

### *Operative Treatment*

Operative treatment is indicated when progressive scoliosis exceeds 45 degrees in patients with an immature skeleton or when progression or associated pain occurs after skeletal maturity. The original surgical technique for scoliosis in adolescents, which was introduced in the 1960s, involved a spinal fusion and internal fixation with a stainless-steel Harrington rod to maintain the spine in a straighter position. At present, in children younger than 10 years of age, implants are placed without fusion to allow continued spinal and chest growth.<sup>20</sup> Improvements in surgical techniques and implants have resulted in reduced complications and improved outcomes. However,



since current techniques still involve spinal fusion over the implant, the tradeoff for the correction of the curvature is a loss of spinal motion. In the thorax, the restriction of rotation is well tolerated, and many patients return to all preoperative activities after surgery. However, spinal fusion extending into the lumbar spine has been associated with reduced activity levels and development of degenerative arthritis. The “flatback” syndrome, a condition characterized by pain and the loss of lumbar lordosis, occurred with the original Harrington distraction technique<sup>21</sup>; it occurs much less frequently with modern segmental spinal instrumentation, which corrects the scoliosis while maintaining an anatomical sagittal posture of balanced thoracic kyphosis and lumbar lordosis. Currently, most surgeons prefer a dual-rod, segmental spinal-fixation system that allows multiple anchor points for attachment to the deformed spine. The typical postoperative hospital stay in the United States is 4 or 5 days, and most adolescents return to school 4 to 6 weeks after the procedure.

As with other procedures involving metallic implants, infection is a major concern. Early postoperative infections (within 3 months) complicate approximately 1% of operations in otherwise healthy adolescents and are usually due to *Staphylococcus aureus* or streptococcus; treatment involves débridement and 4 to 6 weeks of intravenous antibiotic therapy followed by oral antibiotic suppression until the fusion bed is well established. Late-onset infections (>1 year after the operation), generally caused by *Propionibacterium acnes* or *S. epidermidis*, are less common.<sup>22,23</sup> Late-onset or recurrent infection ultimately requires removal of spinal implants, with antibiotic treatment according to culture results to cure vertebral osteomyelitis.<sup>24</sup> Spinal cord injury is a rare complication of surgical correction (incidence, 0.1 to 0.5%)<sup>25</sup>; spinal stenosis, Chiari malformation, tethered spinal cord, and syrinx are risk factors for this complication. MRI of the spinal cord before corrective surgery is indicated in early-onset scoliosis or when clinical findings suggest spinal cord disease. Multimodal intraoperative neurologic monitoring with sensory evoked and motor evoked potentials has supplanted the wake-up test (lightening anesthesia and withholding paralytic agents to assess patient movement in response to verbal commands) for the detection of neurologic deficits during surgery.

Ten years after initial surgery for idiopathic scoliosis, 3 to 10% of patients undergo subsequent surgery.<sup>26,27</sup> A retrospective case series in Sweden involving more than 20 years of follow-up of 156 patients who underwent surgery (91% follow-up) or bracing (87% follow-up) showed similar general health (assessed by means of the 36-Item Short-Form Health Survey) and extent of disability when successful fusion was achieved, although both groups had a higher frequency of back pain, sick-leave days, and degenerative disk disease on radiography as compared with age-matched controls.<sup>28,29</sup>

#### AREAS OF UNCERTAINTY

School-based screening for scoliosis is mandated in some states because of the belief that early detection should lead to improved nonsurgical treatment. Some professional organizations continue to recommend school screening (see Guidelines) even though data are lacking from randomized trials to show that screening results in improved outcomes.

Bracing is frequently used, but its effectiveness remains uncertain. The ongoing BraIST compares bracing with watchful waiting.

The role of surgery is controversial in patients with a mature skeleton and a curvature greater than 50 degrees but without pain or appreciable progression. Natural-history studies show an average rate of progression of 0.75 to 1.00 degree per year, whereas the radiographic measurement of scoliosis is accurate to plus or minus 5 degrees. Consequently, progression may be appreciated only after 5 to 10 years. With the development of pedicle-screw fixation techniques, safe and effective surgical treatment is available for young adults, with results that may be similar or close to those obtained in adolescents. Available data provide support for a strategy of observation and periodic reevaluation for the development of pain or progression; however, rates of surgical complications increase with age.<sup>30</sup>

A genetic-screening test based on identification of single-nucleotide polymorphisms to predict the risk of progression of mild idiopathic scoliosis to scoliosis that requires surgical treatment is commercially available, but it has not been independently validated.<sup>31</sup> Data are currently lacking to indicate that genetic testing adds meaningfully to predictions made on the basis of skeletal maturity and curve magnitude.

## GUIDELINES

Consensus guidelines of the American Academy of Pediatrics, Scoliosis Research Society, American Academy of Orthopaedic Surgeons, and Pediatric Orthopaedic Society of North America<sup>32</sup> recommend screening for scoliosis by means of visual inspection in girls in 5th grade (age 10 to 11 years) and again in 7th grade, and in boys in 8th grade (age 13 to 14 years). Owing to the lack of data to support improved outcomes with such screening, the U.S. Preventive Services Task Force has recommended against routine screening.<sup>33</sup> To my knowledge, there are no professional guidelines for the management of idiopathic scoliosis.

CONCLUSIONS  
AND RECOMMENDATIONS

The patient in the vignette has findings on a physical examination that are typical of idiopathic scoliosis (uneven shoulders, rib prominence on

the forward-bend Adams test, and no skin, extremity, or neurologic findings to suggest a secondary cause). Evaluation should include a posteroanterior spinal radiograph obtained while the patient is in a standing position. If the patient has a curvature of 20 degrees or greater and an immature skeleton, referral to an orthopedic surgeon is appropriate. Brace treatment is commonly recommended for patients with a curve magnitude of 25 to 45 degrees and clinically significant growth remaining, but it requires adherence to the recommended number of hours of treatment (usually  $\geq 12$  hours daily) until the skeleton is mature. In addition, the benefits of brace treatment versus watchful waiting remain unclear, pending results of an ongoing randomized trial. Surgery is indicated in patients with an immature skeleton if progressive scoliosis exceeds 45 degrees.

Dr. Hresko reports receiving travel reimbursement from NuVasive. No other potential conflict of interest relevant to this article was reported.

Disclosure forms provided by the author are available with the full text of this article at NEJM.org.

## REFERENCES

- Wynne-Davies R. Familial (idiopathic) scoliosis: a family survey. *J Bone Joint Surg Br* 1968;50:24-30.
- Riseborough EJ, Wynne-Davies R. A genetic survey of idiopathic scoliosis in Boston, Massachusetts. *J Bone Joint Surg Am* 1973;55:974-82.
- Gorman KF, Julien C, Moreau A. The genetic epidemiology of idiopathic scoliosis. *Eur Spine J* 2012;21:1905-19.
- Sharma S, Gao X, Londono D, et al. Genome-wide association studies of adolescent idiopathic scoliosis suggest candidate susceptibility genes. *Hum Mol Genet* 2011;20:1456-66.
- Bunnell WP. Outcome of spinal screening. *Spine (Phila Pa 1976)* 1993;18:1572-80.
- Yawn BP, Yawn RA, Hodge D, et al. A population-based study of school scoliosis screening. *JAMA* 1999;282:1427-32.
- Weinstein SL, Dolan LA, Spratt KF, Peterson KK, Spoonamore MJ, Ponseti IV. Health and function of patients with untreated idiopathic scoliosis: a 50-year natural history study. *JAMA* 2003;289:559-67.
- Weinstein SL, Zavala DC, Ponseti IV. Idiopathic scoliosis: long-term follow-up and prognosis in untreated patients. *J Bone Joint Surg Am* 1981;63:702-12.
- Dimeglio A, Canavese F. The growing spine: how spinal deformities influence normal spine and thoracic cage growth. *Eur Spine J* 2012;21:64-70.
- Johnston CE, Richards BS, Sucato DJ, Bridwell KH, Lenke LG, Erickson M, Correlation of preoperative deformity magnitude and pulmonary function tests in adolescent idiopathic scoliosis. *Spine (Phila Pa 1976)* 2011;36:1096-102.
- Sanders JO, Khoury JG, Kishan S, et al. Predicting scoliosis progression from skeletal maturity: a simplified classification during adolescence. *J Bone Joint Surg Am* 2008;90:540-53.
- Do T, Frasci C, Burke S, Widmann RF, Rawlins B, Boachie-Adjei O. Clinical value of routine preoperative magnetic resonance imaging in adolescent idiopathic scoliosis: a prospective study of three hundred and twenty-seven patients. *J Bone Joint Surg Am* 2001;83-A:577-9.
- Diab M, Landman Z, Lubicky J, Dormans J, Erickson M, Richards BS. Use and outcome of MRI in the surgical treatment of adolescent idiopathic scoliosis. *Spine (Phila Pa 1976)* 2011;36:667-71.
- Schwend RM, Hennrikus W, Hall JE, Emans JB. Childhood scoliosis: clinical indications for magnetic resonance imaging. *J Bone Joint Surg Am* 1995;77:46-53.
- Nachemson AL, Peterson LE. Effectiveness of treatment with a brace in girls who have adolescent idiopathic scoliosis: a prospective, controlled study based on data from the Brace Study of the Scoliosis Research Society. *J Bone Joint Surg Am* 1995;77:815-22.
- Morton A, Riddle R, Buchanan R, Katz D, Birch J. Accuracy in the prediction and estimation of adherence to brace wear before and during treatment of adolescent idiopathic scoliosis. *J Pediatr Orthop* 2008;28:336-41.
- Janicki JA, Poe-Kochert C, Armstrong DG, Thompson GH. A comparison of the thoracolumbosacral orthoses and Providence orthosis in the treatment of adolescent idiopathic scoliosis: results using the new SRS inclusion and assessment criteria for bracing studies. *J Pediatr Orthop* 2007;27:369-74.
- Katz DE, Herring JA, Browne RH, Kelly DM, Birch JG. Brace wear control of curve progression in adolescent idiopathic scoliosis. *J Bone Joint Surg Am* 2010;92:1343-52.
- Weinstein S, Dolan L. Bracing in Adolescent Idiopathic Scoliosis Trial (BrAIST). *ClinicalTrials.gov* (<http://clinicaltrials.gov/show/NCT00448448>).
- Akbarnia BA, Breakwell LM, Marks DS, et al. Dual growing rod technique followed for three to eleven years until final fusion: the effect of frequency of lengthening. *Spine (Phila Pa 1976)* 2008;33:984-90.
- Cochran T, Irstam L, Nachemson A. Long-term anatomic and functional changes in patients with adolescent idiopathic scoliosis treated by Harrington rod fusion. *Spine (Phila Pa 1976)* 1983;6:576-84.
- Ho C, Skaggs DL, Weiss JM, Tolo VT. Management of infection after instru-

- mented posterior spine fusion in pediatric scoliosis. *Spine (Phila Pa 1976)* 2007;32:2739-44.
23. Ho C, Sucato DJ, Richards BS. Risk factors for the development of delayed infections following posterior spinal fusion and instrumentation in adolescent idiopathic scoliosis patients. *Spine (Phila Pa 1976)* 2007;32:2272-7.
24. Hedequist D, Haugen A, Hresko T, Emans J. Failure of attempted implant retention in spinal deformity delayed surgical site infections. *Spine (Phila Pa 1976)* 2009;34:60-4.
25. Diab M, Smith AR, Kuklo TR. Neural complications in the surgical treatment of adolescent idiopathic scoliosis. *Spine (Phila Pa 1976)* 2007;32:2759-63.
26. Kuklo TR, Potter BK, Lenke LG, Polly DW Jr, Sides B, Bridwell KH. Surgical revision rates of hooks versus hybrid versus screws versus combined anteroposterior spinal fusion for adolescent idiopathic scoliosis. *Spine (Phila Pa 1976)* 2007;32:2258-64.
27. Ramo BA, Richards BS. Repeat surgical interventions following "definitive" instrumentation and fusion for idiopathic scoliosis: five-year update on a previously published cohort. *Spine (Phila Pa 1976)* 2012;37:1211-7.
28. Danielsson AJ, Nachemson AL. Back pain and function 22 years after brace treatment for adolescent idiopathic scoliosis: a case-control study — part I. *Spine (Phila Pa 1976)* 2003;28:2078-85.
29. *Idem*. Back pain and function 23 years after fusion for adolescent idiopathic scoliosis: a case-control study — part II. *Spine (Phila Pa 1976)* 2003;28(18):E373-E383.
30. Smith JS, Shaffrey CI, Glassman SD, et al. Risk-benefit assessment of surgery for adult scoliosis: an analysis based on patient age. *Spine (Phila Pa 1976)* 2011;36:817-24.
31. Ward K, Ogilvie JW, Singleton MV, Chettier R, Engler G, Nelson LM. Validation of DNA-based prognostic testing to predict spinal curve progression in adolescent idiopathic scoliosis. *Spine (Phila Pa 1976)* 2010;35(25):E1455-E1464.
32. Richards BS, Vitale MG. Screening for idiopathic scoliosis in adolescents: an information statement. *J Bone Joint Surg Am* 2008;90:195-8.
33. Screening for idiopathic scoliosis in adolescents: a brief evidence update from the U.S. Preventive Services Task Force. Rockville, MD: U.S. Preventive Services Task Force, 2004 (<http://www.uspreventiveservicestaskforce.org/3rduspstf/scoliosis/scoliors.pdf>).

Copyright © 2013 Massachusetts Medical Society.

#### SPECIALTIES AND TOPICS AT NEJM.ORG

Specialty pages at the *Journal's* website (NEJM.org) feature articles in cardiology, endocrinology, genetics, infectious disease, nephrology, pediatrics, and many other medical specialties. These pages, along with collections of articles on clinical and nonclinical topics, offer links to interactive and multimedia content and feature recently published articles as well as material from the NEJM archive (1812–1989).