



This is an enhanced PDF from The Journal of Bone and Joint Surgery

The PDF of the article you requested follows this cover page.

Abnormal magnetic-resonance scans of the lumbar spine in asymptomatic subjects. A prospective investigation

SD Boden, DO Davis, TS Dina, NJ Patronas and SW Wiesel
J. Bone Joint Surg. Am. 72:403-408, 1990.

This information is current as of September 27, 2006

Reprints and Permissions

Click here to [order reprints or request permission](#) to use material from this article, or locate the article citation on jbjs.org and click on the [Reprints and Permissions] link.

Publisher Information

The Journal of Bone and Joint Surgery
20 Pickering Street, Needham, MA 02492-3157
www.jbjs.org

Abnormal Magnetic-Resonance Scans of the Lumbar Spine in Asymptomatic Subjects

A PROSPECTIVE INVESTIGATION*

BY SCOTT D. BODEN, M.D.[†], DAVID O. DAVIS, M.D.[†], THOMAS S. DINA, M.D.[†],
NICHOLAS J. PATRONAS, M.D.[‡], AND SAM W. WIESEL, M.D.[§], WASHINGTON, D.C.

From the Departments of Orthopaedic Surgery and Radiology, George Washington University Medical Center, Washington

ABSTRACT: We performed magnetic resonance imaging on sixty-seven individuals who had never had low-back pain, sciatica, or neurogenic claudication. The scans were interpreted independently by three neuro-radiologists who had no knowledge about the presence or absence of clinical symptoms in the subjects. About one-third of the subjects were found to have a substantial abnormality. Of those who were less than sixty years old, 20 per cent had a herniated nucleus pulposus and one had spinal stenosis. In the group that was sixty years old or older, the findings were abnormal on about 57 per cent of the scans: 36 per cent of the subjects had a herniated nucleus pulposus and 21 per cent had spinal stenosis. There was degeneration or bulging of a disc at at least one lumbar level in 35 per cent of the subjects between twenty and thirty-nine years old and in all but one of the sixty to eighty-year-old subjects. In view of these findings in asymptomatic subjects, we concluded that abnormalities on magnetic resonance images must be strictly correlated with age and any clinical signs and symptoms before operative treatment is contemplated.

Magnetic resonance imaging is being used increasingly for the diagnosis of conditions causing acute low-back pain and sciatica. Some investigators have proposed that magnetic resonance imaging should replace, rather than supplement, myelography¹². Several have reported that the sensitivity of magnetic resonance imaging for the diagnosis of herniated nucleus pulposus and spinal stenosis is equivalent to or better than that of computerized tomography, even when computerized tomography is combined with myelography or discography^{2,5-8}. Magnetic resonance imaging is sensitive enough to detect a partial or complete tear of the annulus fibrosus that is undetectable with other non-invasive imaging modalities¹⁴.

Despite the high sensitivity of magnetic resonance imaging, there is still a question about whether the modality is acceptably specific, especially when it reveals abnormal findings in the absence of clinical signs and symptoms⁹. Specificity is ordinarily defined by percentages of false-positive and false-negative results, and it is determined most often in symptomatic patients. However, a considerable number of abnormalities are found on the magnetic resonance images of asymptomatic subjects. An abnormal finding on magnetic resonance imaging in an asymptomatic subject is not necessarily a false-positive result, since such a lesion cannot be correlated with an anatomical lesion in subjects who are not operated on. Thus, in this report on asymptomatic subjects, we use the term magnetic-resonance positive to allow inference about the specificity of the findings and to allow calculation of the prevalence of abnormal findings.

Three studies have demonstrated high incidences (24 to 37 per cent) of abnormal findings on discograms, myelograms, and computerized tomography scans of asymptomatic subjects^{3,4,13}. To our knowledge, analogous data have not been generated for magnetic resonance imaging. The purpose of this investigation was to determine the prevalence of positive findings on magnetic resonance images of the lumbar spine in asymptomatic subjects.

Materials and Methods

Magnetic resonance imaging of the lumbar spine was performed on sixty-seven volunteers, who ranged in age from twenty to eighty years (average, forty-two years). There were thirty men and thirty-seven women. The subjects were recruited through advertising in several general newspapers, and the respondents, as well as their spouses (when eligible) were chosen to obtain the correct balance of sex and age for three groups (Fig. 1). The volunteers were screened with a standardized questionnaire, and only those who had no history of pain in the back, sciatica, or neurogenic claudication were included in the study. Any episode of non-radiating low-back discomfort that had lasted more than twenty-four hours or had necessitated time off from work was grounds for excluding the candidate from the study. Volunteers were also excluded if they had had sciatica (pain or sensory abnormalities in the buttocks or

* No benefits in any form have been received or will be received from a commercial party related directly or indirectly to the subject of this article. No funds were received in support of this study.

[†] George Washington University Medical Center, 2150 Pennsylvania Avenue, N.W., Washington, D.C. 20037. Please address requests for reprints to Dr. Boden, Department of Orthopaedic Surgery.

[‡] Department of Radiology, Clinical Center, National Institutes of Health, Bethesda, Maryland.

[§] Department of Orthopaedic Surgery, Georgetown University Medical Center, Washington, D.C. 20007.

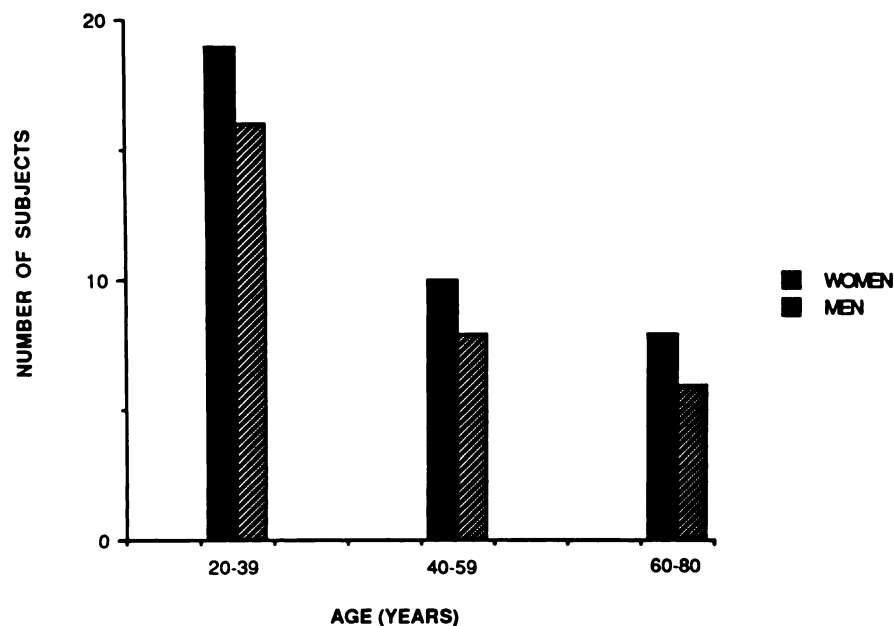


FIG. 1

Demographic data for sixty-seven asymptomatic volunteers.

lower limbs) or if walking caused pain or a sensory abnormality in a lower limb.

Once the subject was entered in the study, multiplanar magnetic-resonance imaging was done from the first lumbar to the first sacral vertebra with a 1.5-tesla imaging system (Signa, General Electric, Milwaukee, Wisconsin). A sagittal localizing series was performed with a repetition time of 400 milliseconds, an echo time of twenty milliseconds, a slice thickness of five millimeters with one-millimeter intervals, and a thirty-two to thirty-six-centimeter field of view. For the sagittal images (twenty-four-centimeter field of view), a multiple spin-echo technique was used, with a repetition time of 1000 milliseconds, to produce five-millimeter-thick slices at one-millimeter intervals after four excitations. Two echoes were generated; the first had an echo time of twenty milliseconds (T1 weighted) and the second, an echo time of seventy milliseconds (T2 weighted). For axial sequences, which were angled through the disc space, four-millimeter-thick slices at one-millimeter intervals were acquired with a repetition time of 600 milliseconds and an echo time of twenty milliseconds.

The sixty-seven studies of the asymptomatic subjects were mixed randomly with thirty-three scans that had been made with the same scanner on patients who had well defined clinical symptoms of either a herniated disc or spinal stenosis. Those symptoms correlated with an unequivocal abnormality on the magnetic resonance image, as previously interpreted by neuroradiologists who were not associated with the study. Thus, 100 scans were presented, in random sequence, to three of us who are neuroradiologists (D. O. D., T. S. D., and N. J. P.) and who had no information about the patients or the subjects. At the level of each disc, any important diagnoses (herniated nucleus pulposus and spinal stenosis) were identified, as were findings of less-

certain importance (bulging and degeneration of a disc). In addition to rating the severity of the abnormality, the neuroradiologist rated his certainty about the diagnosis (definite, probable, or possible).

Since precise radiographic definitions of lesions in the lumbar discs remain subject to variations between readers, this study was designed to yield a spectrum of independent interpretations from three expert neuroradiologists. Herniated nucleus pulposus was considered to be an extrusion, mainly focal, of disc material beyond the osseous confines of the vertebral body, resulting in displacement of epidural fat, nerve root, or thecal sac. A bulge was defined as a diffuse, usually non-focal protrusion of non-osseous material beyond the normal disc space. The basic criterion for a diagnosis of stenosis of the spinal canal was non-discogenic loss of signal in the epidural fat with compression of neural tissues within the canal. Degeneration of the disc

TABLE I
CORRELATION OF AGE WITH ABNORMAL MAGNETIC-RESONANCE IMAGES OF THE LUMBAR SPINE IN SIXTY-SEVEN ASYMPTOMATIC SUBJECTS

	Percentage of Subjects Who Had an Abnormal Finding		
	20-39 Yrs. Old (N = 35)	40-59 Yrs. Old (N = 18)	60-80 Yrs. Old (N = 14)
All abnormal findings			
Reader 1	26	28	57
Reader 2	20	22	64
Reader 3	20	17	50
Average*	22 (7)	22 (3)	57 (7)
Herniated discs	21	22	36
Spinal stenosis	1	0	21

* Figures in parentheses represent the number of subjects in each age group for which the interpretations of all three readers were in complete agreement.

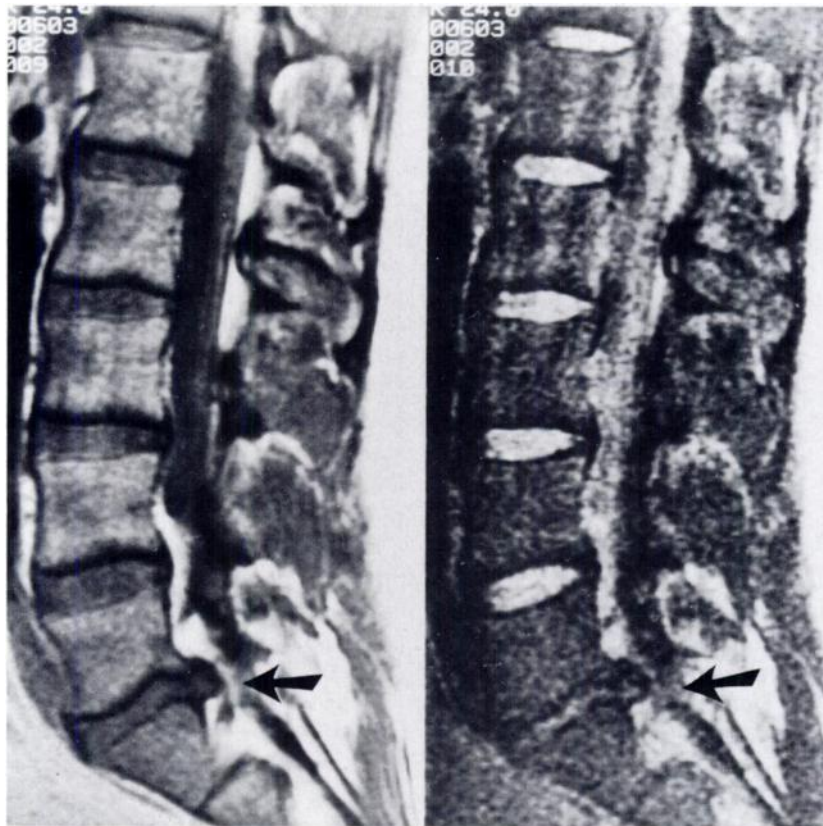


FIG. 2

Magnetic resonance image interpreted by three neuroradiologists as showing herniation of the disc between the fifth lumbar and first sacral vertebrae in a thirty-three-year-old subject who had never had low-back pain or sciatica.

was considered to be present when there was loss of height of the disc space and a decreased signal on T2-weighted sequences.

At the level of each disc, each neuroradiologist scored the findings of the magnetic resonance image quantitatively and objectively and assessed the importance of any abnormal finding subjectively. The results from each reader were averaged, and the diagnosis and the severity of the lesion were tabulated according to the subject's age. Only the findings that the interpreters had labeled as probably or definitely abnormal were recorded as abnormal findings. The over-all number of abnormal magnetic-resonance images included only those that were considered to demonstrate very substantial abnormalities. Findings that were graded as being less important to the diagnosis were tabulated separately. The consistency of interpretation among the neuroradiologists was also assessed. Finally, the percentage of asymptomatic subjects who had abnormal findings was calculated, thus establishing the prevalence of abnormal magnetic-resonance images of the lumbar discs of asymptomatic subjects.

Results

The three neuroradiologists independently interpreted the magnetic resonance images as being substantially abnormal for about 28 per cent (nineteen) of the sixty-seven asymptomatic subjects. Herniated nucleus pulposus was

noted in about 24 per cent (sixteen subjects) and stenosis of the spinal canal, in about 4 per cent (three subjects). Three more subjects had evidence of herniated nucleus pulposus on the magnetic resonance image, but the average of the readings of the three neuroradiologists resulted in a rating of "less than probable". Therefore, these subjects were not included in the group that had an abnormal scan.

The prevalence of abnormal findings was the same in the asymptomatic men and women, but it varied according to the ages of the subjects (Table I). In the twenty to thirty-nine-year-old and forty to fifty-nine-year-old groups, the prevalence of abnormal scans averaged about 20 per cent (seven of thirty-five and four of eighteen, respectively). In the sixty to eighty-year-old group, however, it averaged about 57 per cent (eight of fourteen). The most common important abnormalities in the oldest group were herniated nucleus pulposus (about 36 per cent, or five of fourteen) and stenosis (about 21 per cent, or three of fourteen), whereas all but one of the subjects who were less than sixty years old and had an abnormality had a herniated disc.

Figure 2 shows a magnetic resonance image of a thirty-three-year-old subject who never had back pain. All three interpreters thought that the scan showed a substantially herniated disc between the fifth lumbar and first sacral vertebrae. Most of the herniated discs were between the fourth and fifth lumbar or the fifth lumbar and first sacral levels (Fig. 3).

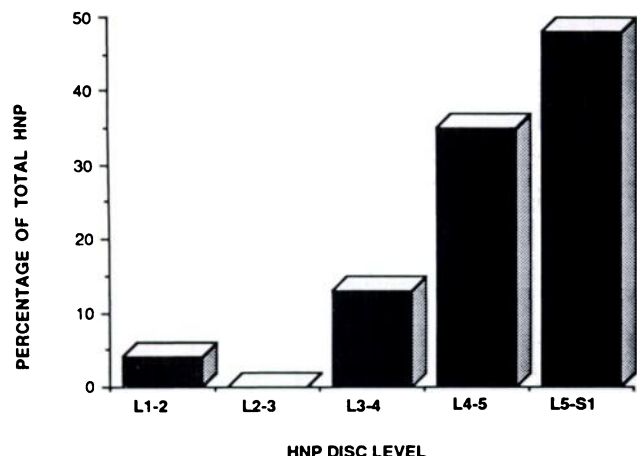


FIG. 3

Distribution of herniated nucleus pulposus (HNP) as seen on magnetic resonance images of the lumbar spine in asymptomatic individuals. Twenty-nine levels in twenty-one volunteers were involved.

At least one bulging disc was seen in about 54 per cent (nineteen) of thirty-five subjects who were less than sixty years old and in 79 per cent (eleven) of the fourteen subjects who were sixty years old or older. Similarly, at least one degenerated disc was noted in 34 per cent (twelve) of the thirty-five subjects in the youngest group and in all but one of the subjects in the oldest group (Fig. 4). In the subjects who were less than sixty years old, the degeneration involved an average of two levels, whereas in each of the subjects who were sixty years old or older, it involved an average of three levels. Approximately half of the degenerated discs also bulged, and this prevalence did not vary with age. In contrast, the proportion of bulging discs that were also degenerated increased from about one-third in the subjects who were less than sixty years old to about two-thirds in the older group.

In all but one of the thirty-three symptomatic patients, the findings on the magnetic resonance image correlated with the operative diagnosis. In the exceptional patient, who had spinal stenosis, one of the involved levels was not identified by two of the three readers.

The three neuroradiologists agreed regarding the presence or absence of abnormal findings on the magnetic resonance image at 99 per cent of the 500 disc levels (five in each subject) from both the symptomatic patients and the asymptomatic subjects. The subjective assessments of the severity of the findings varied somewhat, but over-all the three readers agreed completely on the exact diagnosis at 86 per cent of the levels, two agreed on the diagnosis at 98 per cent, and there was no consensus regarding the diagnosis at only 2 per cent of the levels. With regard to the 335 disc levels of the asymptomatic subjects alone, all three neuroradiologists agreed on the diagnosis at 90 per cent of the levels, and two agreed on the diagnosis at 99 per cent. When there was disagreement, it usually did not involve the presence or absence of an abnormality but rather the precise score of its severity and importance.

Discussion

Substantial percentages of individuals who never had low-back pain or sciatica but had abnormal myelograms (24 per cent), computerized tomography scans (36 per cent), or discograms (37 per cent) have been reported^{3,4,13}. In the present study, about 30 per cent of an asymptomatic population had a major abnormality on a magnetic resonance image of the lumbar spine. The finding that an asymptomatic individual has more than a one-in-four chance of having an abnormal magnetic-resonance image emphasizes the danger of predicating a decision to operate on the basis of any diagnostic tests in isolation, without clinical information. A diagnosis that is based on magnetic resonance imaging,

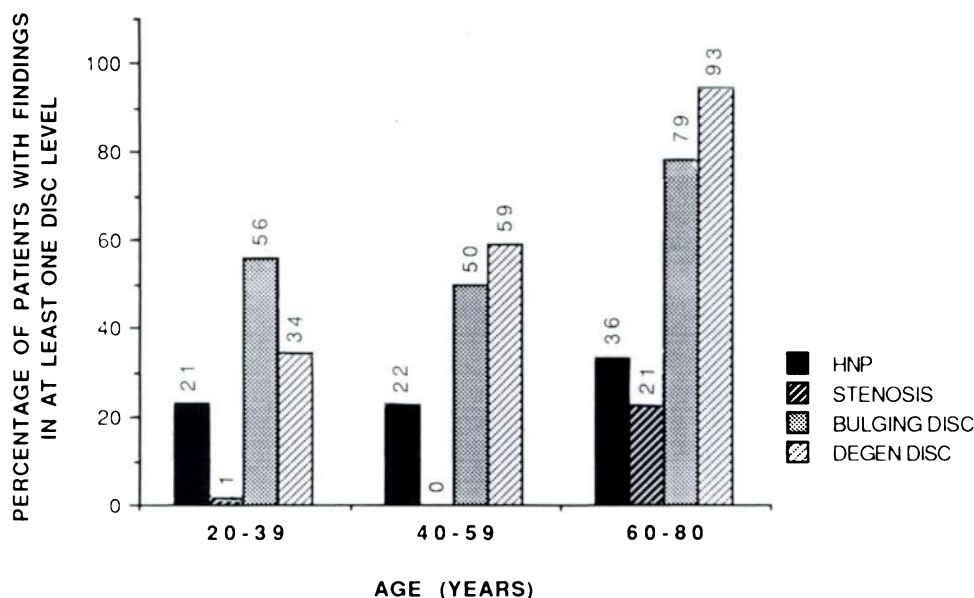


FIG. 4

Incidences of herniated nucleus pulposus (HNP), spinal stenosis, a bulging disc, and a degenerated disc on the magnetic resonance images of sixty-seven asymptomatic individuals.

in the absence of objective clinical findings, may not be the cause of the patient's pain, and an attempt at operative correction could be the first step toward disaster.

Comparison of the results of the present study with those of investigations of other types of imaging in asymptomatic subjects must be undertaken with caution. As we have noted, many abnormal findings are age-dependent. The study of discograms by Holt and the study of myelograms by Hitselberger and Witten differed from our study with regard to the mean age of the subjects. In fact, the results of the other two studies were not analyzed according to age. In contrast, Wiesel et al. studied computerized tomography scans in an asymptomatic population in which the distribution of age was comparable with that in ours. For the subjects who were less than forty years old, the incidences of abnormalities were similar in the two studies, but for the subjects who were forty or older, our data suggested that magnetic resonance imaging may yield fewer positive findings than computerized tomography does (approximately 35 per cent compared with approximately 50 per cent). Magnetic resonance imaging may be even more superior than the studies suggested because the computerized tomography was done at the fourth and fifth lumbar and the fifth lumbar and first sacral levels only, while the magnetic resonance images demonstrated herniated discs at the third and fourth lumbar levels as well. In fact, 13 per cent (four) of all twenty-nine herniated discs in our asymptomatic subjects were at these levels.

As with computerized tomography, subjects who were sixty years old or older were found to have a far higher percentage of abnormal magnetic-resonance scans than did those who were younger than sixty. Thus, an abnormal magnetic-resonance image in a younger patient is more likely to be a true indication of the cause of the complaints. For individuals who are sixty years old or older, it is less likely that the lesions demonstrated by magnetic resonance imaging are of clinical importance.

The interpretations of the three neuroradiologists in our study varied substantially less than those of the investigators of the computerized tomography scans¹³. In our study, the neuroradiologists agreed completely about 60 per cent of the scans, whereas the investigators did so about only 11 per cent of the computerized tomography scans. As noted earlier, the disagreements in our study mainly concerned the severity of the findings. Accordingly, one might infer that magnetic resonance imaging is better than computerized tomography for assessing the size and importance of lesions and of neural compression. However, that inference could be validated only if the same team of radiologists interpreted both computerized tomography scans and magnetic resonance images for the same group of patients.

The sensitivity of magnetic resonance imaging also enabled us to study the incidence and distribution of bulging and degenerated discs. In addition to the surprisingly high prevalence of those findings in asymptomatic subjects of all ages (twenty years old or older), the interrelationships of the two findings differed from what had been expected.

Although many authors have considered bulging of a disc to be caused by degeneration^{5,6}, in our asymptomatic subjects only half of the degenerated discs bulged, and only half of the bulging discs were also degenerated. In addition, in the older subjects, the prevalence of degeneration was more increased than that of bulging. These relationships may suggest that factors other than degeneration result in bulging, or possibly that the T2-weighted magnetic-resonance-imaging sequences do not detect all lesions that are indicative of degenerated discs¹⁵.

In analyzing the reliability of data like ours, it is important to consider the selection of subjects as related to the design of the study. For the asymptomatic subjects in this study, the distribution of age and sex (Fig. 1) was similar to the typical spectrum for patients who have low-back pain^{1,10,11}. Our three groups contained approximately equal numbers of men and women (by design) and most subjects were less than sixty years old. In addition, in our study, the distribution of the levels of the herniated discs was similar to that in a large study of patients who were treated for herniation of a lumbar disc¹¹.

Another important aspect of our selection of subjects was the exclusion of those who had any history of back pain, sciatica, or neurogenic claudication. It is possible, especially with older patients, that an episode of pain in the back might be forgotten, but we tried to minimize this error by using a standardized questionnaire that elicited the necessary information with several different avenues of questioning. Subjects whose reliability was questionable or who had problems with memory were excluded from the study.

We designed the prospective study to maximize the reliability of the neuroradiologists' estimates of the abnormalities on the magnetic resonance images. The asymptomatic volunteers were examined with a complete and standardized imaging protocol that was identical to the one used for the symptomatic patients. Precautions were taken so that the scans of the asymptomatic subjects could not be distinguished on a technical basis from those of the symptomatic patients. We randomized the sequence in which the scans were read so that the neuroradiologists' interpretation would be blind and unbiased by knowledge of the clinical situation. The forced-choice design of the score sheet necessitated evaluation of each disc level for the four objective findings and was intended to minimize inadvertent under-reporting of findings. Finally, our three neuroradiologists differed in training, experience, and type of practice (private or academic), so that the spectrum of interpretation for each scan would be as wide as possible.

In conclusion, the high incidence of bulging and degenerated lumbar intervertebral discs seen on the magnetic resonance images of asymptomatic subjects confirms observations that have been made with computerized tomography and myelography studies that these findings are part of a normal, or at least common, aging process. The finding of an abnormal lumbar disc on a magnetic resonance image is most reliable in symptomatic patients who are less than sixty years old. It is less reliable in older patients. In this

study, the prevalence of abnormal magnetic-resonance images for asymptomatic subjects who were less than forty years old was comparable with that reported by Wiesel et al. for computerized tomography scans. Finally, the finding of substantial abnormalities of the lumbar spine in about 28

per cent of asymptomatic subjects emphasizes the dangers of predicating a decision to operate on the basis of diagnostic tests — even when a state-of-the-art modality is used — without precise correlation with clinical signs and symptoms.

References

1. FRYMOYER, J. W.: Back Pain and Sciatica. *New England J. Med.*, **318**: 291-300, 1988.
2. GIBSON, M. J.; BUCKLEY, J.; MAWHINNEY, R.; MULHOLLAND, R. C.; and WORTHINGTON, B. S.: Magnetic Resonance Imaging and Discography in the Diagnosis of Disc Degeneration. A Comparative Study of 50 Discs. *J. Bone and Joint Surg.*, **68-B(3)**: 369-373, 1986.
3. HITSELBERGER, W. E., and WITTEN, R. M.: Abnormal Myelograms in Asymptomatic Patients. *J. Neurosurg.*, **28**: 204-206, 1968.
4. HOLT, E. P., JR.: The Question of Lumbar Discography. *J. Bone and Joint Surg.*, **50-A**: 720-726, June 1968.
5. MARAVILLA, K. R.; LESH, PHILIP; WEINREB, J. C.; SELBY, D. K.; and MOONEY, VERT: Magnetic Resonance Imaging of the Lumbar Spine with CT Correlation. *Am. J. Neuroradiol.*, **6**: 237-245, 1985.
6. MASARYK, T. J.; ROSS, J. S.; MODIC, M. T.; BOUMPHREY, FRANCIS; BOHLMAN, HENRY; and WILBER, GEOFFREY: High-Resolution MR Imaging of Sequestered Lumbar Intervertebral Disks. *Am. J. Neuroradiol.*, **9**: 351-358, 1988.
7. MODIC, M. T.; MASARYK, THOMAS; BOUMPHREY, FRANCIS; GOORMASTIC, MARLENE; and BELL, GORDON: Lumbar Herniated Disk Disease and Canal Stenosis: Prospective Evaluation by Surface Coil MR, CT, and Myelography. *Am. J. Neuroradiol.*, **7**: 709-717, 1986.
8. OSBORN, A. G.; HOOD, R. S.; SHERRY, R. G.; SMOKER, W. R. K.; and HARNSBERGER, H. R.: CT/MR Spectrum of Far Lateral and Anterior Lumbosacral Disc Herniations. *Am. J. Neuroradiol.*, **9**: 775-778, 1988.
9. ROTHMAN, R. H.: A Study of Computer-Assisted Tomography. Introduction. *Spine*, **9**: 548, 1984.
10. THOMAS, A. M. C., and AFSHAR, F.: The Microsurgical Treatment of Lumbar Disc Protrusion. Follow-up of 60 Cases. *J. Bone and Joint Surg.*, **69-B(5)**: 696-698, 1987.
11. WEINSTEIN, J.; SPRATT, K. F.; LEHMANN, T.; MCNEILL, T.; and HEJNA, W.: Lumbar Disc Herniation. A Comparison of the Results of Chemonucleolysis and Open Discectomy after Ten Years. *J. Bone and Joint Surg.*, **68-A**: 43-54, Jan. 1986.
12. WEISZ, G. M.; LAMOND, T. S.; and KITCHENER, P. N.: Spinal Imaging: Will MRI Replace Myelography? *Spine*, **13**: 65-68, 1988.
13. WIESEL, S. W.; TSOURMAS, NICHOLAS; FEFFER, H. L.; CITRIN, C. M.; and PATRONAS, NICHOLAS: A Study of Computer-Assisted Tomography. 1. The Incidence of Positive CAT Scans in an Asymptomatic Group of Patients. *Spine*, **9**: 549-551, 1984.
14. YU, SHIWEI; SETHI, L. A.; HO, P. S. P.; WAGNER, MARVIN; and HAUGHTON, V. M.: Tears of the Anulus Fibrosus: Correlation between MR and Pathologic Findings in Cadavers. *Am. J. Neuroradiol.*, **9**: 367-370, 1988.
15. ZUCHERMAN, JAMES; DERBY, RICHARD; HSU, KEN; GOLDTHWAITE, NOEL; WHITE, ARTHUR; and PICETTI, GEORGE: MRI Scan Does Not Replace Discography. *Orthop. Trans.*, **13**: 16, 1989.